



Executive Functioning White Matter Structures Supporting Language Recovery in Post-Stroke Aphasia

Celia Litovsky, Swathi Kiran, Cynthia Thompson, David Caplan,
Todd Parrish and Brenda Rapp

EasyChair preprints are intended for rapid dissemination of research results and are integrated with the rest of EasyChair.

August 17, 2021

Executive functioning white matter structures supporting language recovery in post-stroke aphasia

Celia P. Litovsky^{1*}, Swathi Kiran², Cynthia Thompson³, David Caplan⁴, Todd Parrish⁵, and Brenda Rapp¹

¹ Department of Cognitive Science, Johns Hopkins University, Baltimore, MD, USA

² Department of Speech, Language, and Hearing Sciences, Boston University, Boston, MA, USA

³ Department of Communication Sciences and Disorders, Northwestern University, Evanston, IL, USA

⁴ Department of Neurology, Massachusetts General Hospital, Boston, MA, USA

⁵ Department of Radiology, Northwestern University, Evanston, IL, USA

Introduction

There has been increasing interest in understanding the role of executive processes (e.g., cognitive control, selection, working memory) in the recovery of post-stroke language deficits. Cortical executive function regions have been shown to be recruited for language both in post-stroke aphasia and in healthy subjects performing difficult language tasks [1]. Researchers have also found that executive regions play a major role in recovery from aphasia [2]. However, little research has evaluated whether white matter tracts involved in executive functions support language recovery [3]-[4].

Here, we specifically evaluated if white matter integrity (measured by tract volume) of segments of the corpus callosum, bilateral cingulum, and bilateral IFOF predicted a) pre-treatment written and spoken ability and b) treatment effectiveness (for trained and untrained items) in chronic post-stroke participants who received language therapy for sentence processing, naming, or spelling impairments.

Methods

Fifty-eight participants (19 female, 58 ± 1.6 years, 59 ± 6.9 months post-stroke) with a single left-hemisphere stroke underwent T1-weighted and diffusion-weighted imaging ($b=0$, 1500 s/mm²) and completed a three-month behavioral spelling, naming, or sentence processing rehabilitation. Eleven age-matched healthy controls (8 female, 62 ± 3.4 years) underwent the same scanning protocol. Whole-brain deterministic tractography was performed in ExploreDTI [5] using constrained spherical deconvolution [6], and seven white matter tracts (three segments of the corpus callosum, bilateral cingulum, bilateral IFOF) were segmented according to standard protocols [7]-[8]. Each tract's volume was normalized by the participant's right hemisphere white matter volume to control for between-subject differences in brain size. Normalized tract volumes were entered into stepwise regression models to predict pre-treatment language ability (spelling, naming, and sentence processing), improvement on trained items, and generalization to untrained items.

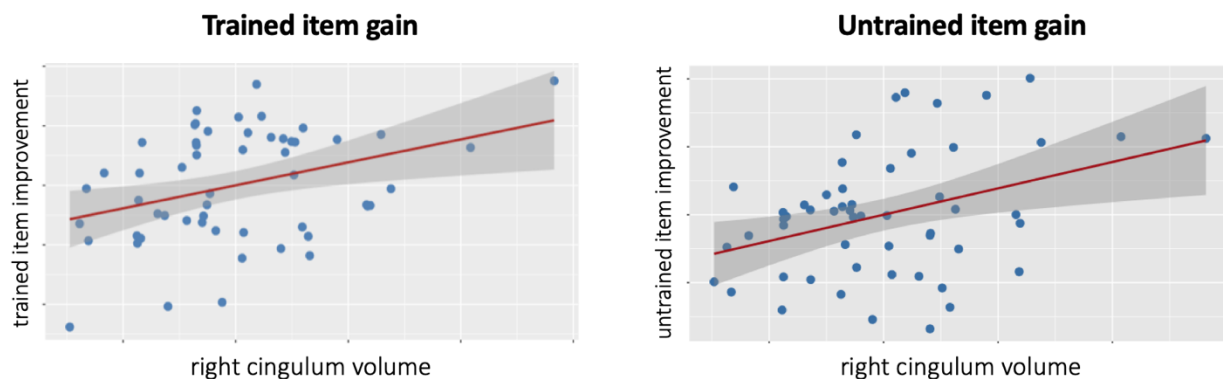
Results

(1) Behavioral measures of executive functions at the pre-treatment time point were significantly associated with pre-treatment spelling ($p < .05$), spoken naming ($p < .01$), and sentence processing ($p < .05$) severity of impairment. However, these behavioral measures were not significantly associated with the magnitude of response to language treatment (all $ps > .1$). (2) Neural analysis found that executive white matter tract integrity significantly predicted both: pre-treatment language severity [spelling: $p < .001$, spoken naming: $p < .05$, sentence processing: $p < .01$] and response to treatment on trained ($p < .05$) and untrained ($p < .05$) items. (3) Specifically, volumes of the genu of the corpus callosum ($p < .05$) and right cingulum ($p < .01$) explained significant and unique variance in trained and untrained item improvement. (4) Volumes of the genu and right cingulum were also significantly greater in post-stroke individuals than in age-matched healthy control participants ($ps < .001$).

Conclusions

Volumes of two white matter tracts associated with executive processes (genu and right cingulum) were found to be associated both with severity of language deficits and with extent of improvement following language therapy. These results are consistent with and extend previous evidence indicating relevance of executive brain regions in post-stroke language recovery [2]. We also report, for the first time, evidence of significant post-stroke neuroplasticity (increased WM volume relative to controls) in executive white matter structures.

Figure



Partial correlation plots indicating a positive relationship between stroke participants' tract volume of the right cingulum with trained and untrained item improvement.

References

- [1] Brownsett, S.L.E., Warren, J.E., Geranmayeh, F., Woodhead, Z., Leech, R., & Wise, R.J.S. (2014). Cognitive control and its impact on recovery from aphasic stroke. *Brain*, 137, 242-254.
- [2] Geranmayeh, F., Wing Chau, T., Wise, R.J.S., Leech, R., & Hampshire, A. (2017). Domain-general subregions of the medial prefrontal cortex contribute to recovery of language after stroke. *Brain*, 140, 1947-1958.

- [3] Strenziok, M., Greenwood, P.M., Santa Cruz, S.A., Thompson, J.C., & Parasuraman, R. (2014). Differential contributions of dorso-ventral and rostro-caudal prefrontal white matter tracts to cognitive control in healthy older adults. *PLoS One*, 8(12), e81410.
- [4] Lin, Y.-C., Shih, Y.-C., Tseng, W.-Y., I., Chu, Y.-H., Wu, M.-T., Chen, T.-F., Tang, P.-F., Chiu, M.-J. (2014). Cingulum correlates of cognitive functions in patients with mild cognitive impairment and early Alzheimer's disease: A diffusion spectrum imaging study. *Brain Topography*, 27, 393-402.
- [5] Leemans, A., Jeurissen, B., Sijbers, J., & Jones, D.K. (2009). ExploreDTI: A graphical toolbox for processing, analyzing, and visualizing diffusion MR data. *Proceedings of the 17th Scientific Meeting, International Society for Magnetic Resonance in Medicine*, Honolulu, HI, p. 3537.
- [6] Jeurissen, B., Leemans, A., Jones, D.K., Tournier, J.D. & Sijbers, J. (2011). Probabilistic fiber tracking using the residual bootstrap with constrained spherical deconvolution. *Human Brain Mapping*, 32(3), 461-479.
- [7] Catani, M. & Thiebaut de Schotten, M. (2008). A diffusion tensor imaging tractography atlas for virtual in vivo dissections. *Cortex*, 44, 1105-1132.
- [8] Hofer, S., & Frahm, J. (2006). Topography of the human corpus callosum revisited – Comprehensive fiber tractography using diffusion tensor magnetic resonance imaging. *NeuroImage*, 32(3), 989-994.

Acknowledgments

The authors thank the participants for the time and effort that they devoted to the research. This work was funded by NIH grants DC012283 to Brenda Rapp, Cynthia Thompson, and Swathi Kiran; and NSF GRFP fellowship DGE-1746891 to Celia Litovsky.